

ISSN Print: 1813-176x
ISSN Online: 1994-4624

International Journal of Molecular Medicine and Advance Sciences
https://ijmmas.com/

Research Article

The "Spinal-First, Injection-Last" Technique: A Modified Thoraco-Lumbar Combined Spinal-Epidural Double-Space Approach for Total Abdominal Hysterectomy.

Dr. Dasari Shivaprasad[1]*, Dr. Pampana Bhuvanchandrakanth[2], Dr. Vadla Shravan Kumar[3], Dr. Manchikanti V D Avinash[4].

[1]Professor, Department of Anesthesia, Mamatha Institute of Medical Sciences, Bachupally, Hyderabad, Telangana, India.
[2]Assistant Professor, Department of Anesthesia, Mamatha Institute of Medical Sciences, Bachupally, Hyderabad, Telangana, India.
[3]Assistant Professor, Department of Anesthesia, Mamatha Institute of Medical Sciences, Bachupally, Hyderabad, Telangana, India.
[4]Senior Resident, Department of Anesthesia, Mamatha Institute of Medical Sciences, Bachupally, Hyderabad, Telangana, India.

Correspondence:
Dr. D. Shivaprasad.

Email: shiva.dr.dasari@gmail.com

Received: 08-10-2026
Revised: 23-10-2026
Accepted: 04-11-2026
Published: 18-11-2026

DOI: 10.61336/ijmmas.22-04-32

Abstract: ***Background:*** The combined spinal-epidural (CSE) technique offers the rapid onset of spinal anaesthesia with the flexibility of epidural top-ups and postoperative analgesia. The conventional dual-space CSE, though anatomically appealing, carries a theoretical risk of catheter shearing when a lumbar epidural catheter is inadvertently transfixed by a subsequently introduced spinal needle at a higher interspace. We describe a modified thoraco-lumbar double-space CSE that resequences the workflow to structurally eliminate this risk. ***Methods:*** In this prospective observational study, 45 ASA I–II women scheduled for elective total abdominal hysterectomy (TAH) underwent CSE using the "Spinal-First, Injection-Last" technique. A 25G Quincke spinal needle was introduced at T11–T12 and secured after CSF confirmation, without injection. An 18G Tuohy needle was then used to identify the epidural space between L1–L3, and a catheter was threaded 4–5 cm cephalad, injection 12.5 mg of 0.5% hyperbaric bupivacaine with 25 µg fentanyl injected through the pre-placed thoracic spinal needle followed by fixation of epidural catheter . Block characteristics, haemodynamics, complications and postoperative analgesia were recorded. ***Results:*** The technique was successful in all 45 patients (100%). Median time to sensory block at T6 was 4 (3–6) minutes and to Bromage 3 motor block was 5 (4–7) minutes. Peak sensory level was T6 (T5–T7). No catheter shearing, post-dural puncture headache or neurological deficit was recorded. Hypotension requiring vasopressor occurred in 12 (26.7%) patients. Mean duration of surgical anaesthesia was 182 ± 21 minutes; postoperative epidural analgesia produced a mean VAS at rest of 2.1 ± 0.8 at 24 hours. ***Conclusion:*** The "Spinal-First, Injection-Last" thoraco-lumbar CSE technique is a safe, reproducible modification that structurally eliminates catheter shearing risk while delivering the dense surgical block and prolonged analgesia required for TAH.

Keywords: Combined spinal-epidural anaesthesia; Total abdominal hysterectomy; Thoracic spinal anaesthesia; Catheter shearing; Regional anaesthesia; Dual-space technique.

Copyright @ 2026: This is an open-access article distributed under the terms of the Creative Commons Attribution license which permits unrestricted use, distribution and reproduction in any medium for non-commercial use (NonCommercial, or CC-BY-NC) provided the original author and source are credited.

INTRODUCTION

Total abdominal hysterectomy (TAH) remains one of the most frequently performed major gynaecological surgeries worldwide and imposes significant somatic, visceral and postoperative analgesic demands on the anaesthetic technique.[1,2] While general anaesthesia (GA) with endotracheal intubation is a traditional choice, neuraxial techniques offer well-documented benefits including reduced blood loss, attenuated surgical stress response, decreased opioid requirement, earlier return of bowel function, and a lower incidence of postoperative nausea and vomiting.[3–5]

Single-shot spinal anaesthesia provides a rapid, dense and reliable block but is limited by a finite duration that is often inadequate for hysterectomies, particularly when adhesions, endometriosis or malignancy prolong operative time.[6] Continuous epidural anaesthesia offers titratable, prolonged analgesia but is limited by slow onset, patchy block, and higher failure rates when used as the sole surgical anaesthetic.[7,8] The combined spinal-epidural (CSE) technique was developed to marry the reliability of spinal anaesthesia with the flexibility of epidural top-ups and postoperative analgesia.[9–11]

Two principal approaches to CSE are described: the single-space needle-through-needle (NTN) technique and the dual-space (or double-space) technique.[12,13] In the NTN method, a Tuohy needle is first placed in the epidural space and a longer spinal needle is passed coaxially through it to breach the dura. Although widely adopted, NTN is associated with failed dural puncture despite correct epidural placement, metallic particle generation, epidural catheter migration through the dural rent, and the inability to test the epidural catheter before spinal drug injection.[14–17]. The dual-space technique addresses several of these concerns by allowing independent placement and testing of the epidural catheter and the spinal block at separate interspaces.[18] However, when the conventional sequence is followed—first the epidural catheter at a lower interspace, then the spinal at a higher interspace—the advancing spinal needle can inadvertently transfix the previously placed catheter ("through-and-through" needle

laceration), with catheter shearing on withdrawal.[19–21] Multiple case reports describe retained catheter fragments requiring surgical retrieval following such injuries.[22,23]

For pelvic surgery such as TAH performed through a Pfannenstiel incision, the segmental innervation to be blocked comprises a well-defined territory: uterine visceral and somatic afferents ascend via T10–L1, with sympathetic fibres travelling through the uterine, pelvic and inferior/superior hypogastric plexuses into the lumbar splanchnic nerves; the parietal peritoneum of the pelvis draws its somatic supply from T11–L1; and the anterior abdominal wall — the rectus abdominis, pyramidalis, and the external oblique, internal oblique and transverse abdominis muscles — is innervated segmentally from T7–L1, with the skin over the Pfannenstiel incision supplied by the iliohypogastric and ilioinguinal nerves (T12–L1).[24,25] A spinal block placed at T11–T12 therefore covers this entire territory in a single injection: the rectus and lateral abdominal wall muscles become flaccid, retraction of the Pfannenstiel wound is effortless for the operating surgeon, and uterine traction pain — with its associated vagally-mediated bradycardia and nausea — is abolished, yielding a quiet, well-relaxed surgical field. A lumbar spinal block, however dense, often produces an insufficiently high level for peritoneal traction pain, whereas a lumbar epidural alone is slow and unreliable for surgical anaesthesia. Low-thoracic spinal anaesthesia has therefore emerged as a safe and effective alternative, producing rapid, high-quality abdominal wall relaxation at reduced local anaesthetic doses.[26–28]

We hypothesised that a modified thoraco-lumbar double-space CSE, in which the spinal needle is placed and parked at T11–T12 first, the lumbar epidural catheter is threaded next between L1–L3, and the spinal anaesthetic is injected last through the pre-placed thoracic needle, would (a) structurally eliminate the possibility of the spinal needle transfixing the epidural catheter, (b) permit unhurried epidural catheter placement without racing against a rising sensory block, and (c) provide dense low-thoracic surgical anaesthesia with an intact lumbar epidural for postoperative analgesia. We present the technique, its rationale, and our initial clinical experience.

MATERIALS AND METHODS

Study design and setting

This prospective observational study was conducted in the Department of Anaesthesiology, Mamata Academy of Medical Sciences, Bachupally, Hyderabad, over a period of 12 months (January 2025 – January 2026), after obtaining approval from the Institutional Ethics Committee (IEC No: MAMS/2024/AN/17) and written informed consent from all participants. The study conformed to the Declaration of Helsinki and was prospectively registered with the Clinical Trials Registry–India.[29]

Participants

Consecutive adult women, aged 30–65 years, of American Society of Anesthesiologists (ASA) physical status I or II, scheduled for elective TAH under regional anaesthesia were enrolled. Exclusion criteria were: patient refusal, coagulopathy or ongoing anticoagulant therapy, local infection at the puncture site, known allergy to local anaesthetics, pre-existing neurological deficit, severe cardiovascular disease, gross spinal deformity, and body mass index (BMI) > 35 kg/m^2. A sample size of 45 was chosen based on a pilot audit of expected block characteristics using a precision-based approach with $\alpha = 0.05$ and an anticipated 90% success rate.[30]

Preoperative preparation

All patients underwent standard preoperative evaluation including complete blood count, coagulation profile, renal and hepatic function tests, electrocardiography and chest radiography where indicated. Patients were fasted for 8 hours for solids and 2 hours for clear fluids per institutional protocol. Oral pantoprazole 40 mg and alprazolam 0.25 mg were administered on the night before surgery.[31]

Intraoperative management

In the operating room, standard monitoring including 5-lead electrocardiography, non-invasive blood pressure at 3-minute intervals, and pulse oximetry was established. An 18G intravenous cannula was secured and co-loading with 10 mL/kg of Ringer's lactate solution was commenced.[32]

The "Spinal-First, Injection-Last" technique

With the patient in the sitting position, the T11–T12 and L1–L2/L2–L3 interspaces were identified using surface landmarks (the T7 inferior scapular angle and Tuffier's line) and confirmed by counting.[33] The back was prepared with 2% chlorhexidine in 70% alcohol and draped aseptically.

Step 1 — Spinal First (dural puncture only): Local infiltration with 2 mL of 2% lignocaine was performed at T11–T12. A 25G Quincke spinal needle was introduced via a paramedian/midline approach with a slight cephalad angulation. On free flow of clear cerebrospinal fluid (CSF), the stylet was immediately reinserted; injection of the local anaesthetic was deliberately deferred. The

hub of the needle was stabilised between the operator's non-dominant thumb and index finger, keeping the shaft strictly stationary.

Step 2 — Epidural Next (catheter placement): Without disturbing the spinal needle, the L1–L2 or L2–L3 interspace was infiltrated, and an 18G Tuohy needle was advanced through a midline or paramedian approach. The epidural space was identified using the loss-of-resistance-to-air technique, and a 20G multi-orifice catheter was threaded 4–5 cm into the epidural space in a cephalad direction.[34] The Tuohy needle was withdrawn over the catheter, and a test dose of 3 mL of 2% lignocaine with adrenaline 1:200 000 was administered to exclude intravascular or intrathecal placement.[35]

Step 3 — Injection Last (spinal drug delivery): The stylet of the pre-placed thoracic spinal needle was removed, free CSF flow was reconfirmed, and 2.5 mL of 0.5% hyperbaric bupivacaine (12.5 mg) with 25 µg fentanyl (total volume 3 mL) was injected slowly over 15 seconds.[36]

Step 4 — Catheter Safe (fixation): The spinal needle was withdrawn, and the epidural catheter was fixed with a transparent adhesive dressing. The patient was immediately positioned supine.



Figure 1. Loss-of-resistance-to-air technique used to identify the epidural space at the L1–L2 / L2–L3 interspace during Step 2 (Epidural Next). The 20G multi-orifice epidural catheter tail (transparent tubing on the right) has been threaded 4–5 cm cephalad into the epidural space before any intrathecal drug is injected — hence "catheter first, injection last."

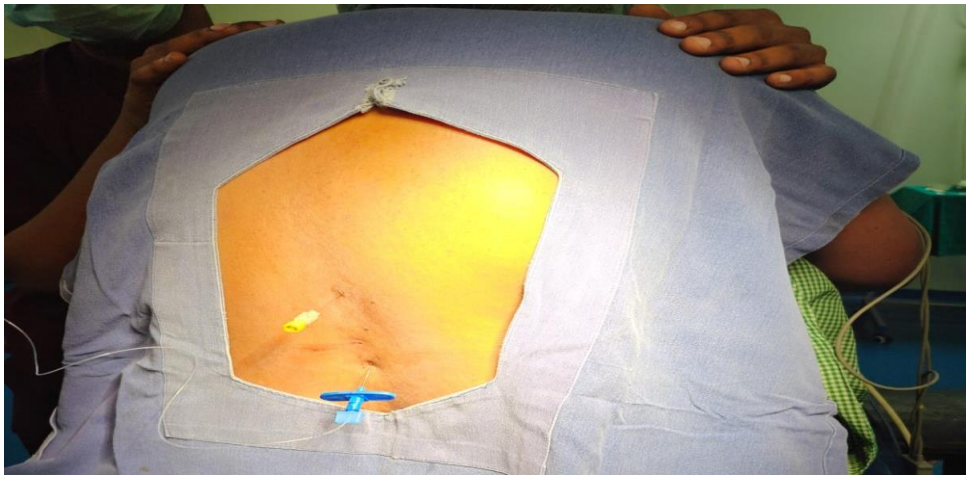

Figure 2. Bilevel needle placement immediately before intrathecal injection (Step 3, Injection Last). The 25G Quincke spinal needle (yellow hub, upper puncture) is parked at the T11–T12 interspace with the stylet in situ after successful CSF confirmation, while the 18G Tuohy needle / secured epidural catheter (blue, lower puncture) sits at the L1–L2 / L2–L3 interspace. Because the spinal needle remains stationary throughout epidural catheter threading and the two puncture sites are anatomically separated, mechanical transfixion of the catheter by the spinal needle is structurally impossible.

Because the spinal needle was static during epidural catheter placement, and because the T11–T12 spinal puncture site was cephalad to the L1–L3 catheter trajectory, there was no opportunity for the sharp bevel of the spinal needle to contact or transfix the catheter—the key mechanical advantage of this resequenced workflow.

Block assessment and intraoperative care

Sensory block was assessed by loss of pinprick sensation every 1 minute for the first 10 minutes, then every 5 minutes until fixation. Motor block was graded on the modified Bromage scale.[37] The following variables were recorded: time from spinal injection to onset of sensory block at T10, time to peak sensory level, time to Bromage 3 motor block, and duration of surgical anaesthesia (time from spinal injection to first request for epidural top-up or onset of pain during surgery). Hypotension (systolic BP < 90 mm Hg or a > 20% decrease from baseline) was treated with incremental intravenous ephedrine boluses of 6–12 mg (prepared by diluting a 30 mg ampoule to 5 mL, giving 6 mg/mL) together with rapid fluid loading; in our practice, phenylephrine is not routinely used for spinal-induced hypotension in this setting. Bradycardia (heart rate < 50 beats/min) was treated with intravenous atropine 0.6 mg. Epidural top-ups with 3–5 mL of 0.5% bupivacaine were administered if the sensory level regressed or the patient reported discomfort during surgery.

Postoperative analgesia

Epidural analgesia with 0.125% bupivacaine plus fentanyl 2 µg/mL at the rate of 4ml/hr was initiated at a background infusion with syringe pump.[38] Pain was assessed on a 0–10 visual analogue scale (VAS) at 2, 6, 12, 24 and 48 hours postoperatively. Rescue analgesia (intravenous tramadol 50 mg) was provided if VAS > 4.

Outcome measures

Primary outcomes were procedural success (defined as adequate surgical anaesthesia without conversion to GA) and epidural catheter integrity on removal. Secondary outcomes included block characteristics, intraoperative haemodynamic stability, postoperative pain scores, and complications (post-dural puncture headache, transient neurological symptoms, urinary retention, backache, and catheter-related complications).

Statistical analysis

Data were analysed using SPSS version 26.0 (IBM Corp, Armonk, NY, USA). Continuous variables were presented as mean ± standard deviation or median (interquartile range) as appropriate; categorical variables as counts and percentages. Normality was assessed with the Shapiro–Wilk test. A p-value < 0.05 was considered statistically significant.

RESULTS

A total of 45 patients were enrolled and completed the study. Demographic and baseline characteristics are summarised in Table 1.

Table 1. Demographic and baseline characteristics (n = 45)

Variable	Value
Age (years), mean ± SD	46.3 ± 7.8
Weight (kg), mean ± SD	62.4 ± 8.5
Height (cm), mean ± SD	157.6 ± 5.4
BMI (kg/m²), mean ± SD	25.1 ± 3.2
ASA I / II, n (%)	27 (60.0) / 18 (40.0)
Duration of surgery (min), mean ± SD	118 ± 24
Indication for TAH, n (%)	
Fibroid uterus	26 (57.8)
Adenomyosis	9 (20.0)
Dysfunctional uterine bleeding	6 (13.3)
Ovarian pathology	4 (8.9)

Procedural details and block characteristics

The technique was successfully performed in all 45 patients (100%). CSF was obtained at the first spinal puncture attempt in 42 patients (93.3%); the remaining three required a single repositioning of the needle. The epidural catheter was threaded without difficulty in all cases. No visible or occult catheter damage was noted on removal, giving a catheter integrity of 100%. Onset characteristics of the block are summarised in Table 2 and depicted graphically in Figure 3.

Table 2. Block characteristics of the thoraco-lumbar CSE (n = 45)

Parameter	Value (n = 45)
Time to sensory block at T10 (min), median (IQR)	2 (2–3)
Time to sensory block at T6 (min), median (IQR)	4 (3–6)
Time to Bromage 3 motor block (min), median (IQR)	5 (4–7)
Peak sensory level, median (range)	T6 (T5–T7)
Duration of surgical anaesthesia (min), mean ± SD	182 ± 21
Number of intraoperative epidural top-ups, median (IQR)	0 (0–1)
Two-segment regression time (min), mean ± SD	96 ± 18
Need for conversion to GA, n (%)	0 (0)
Catheter integrity on removal, n (%)	45 (100)

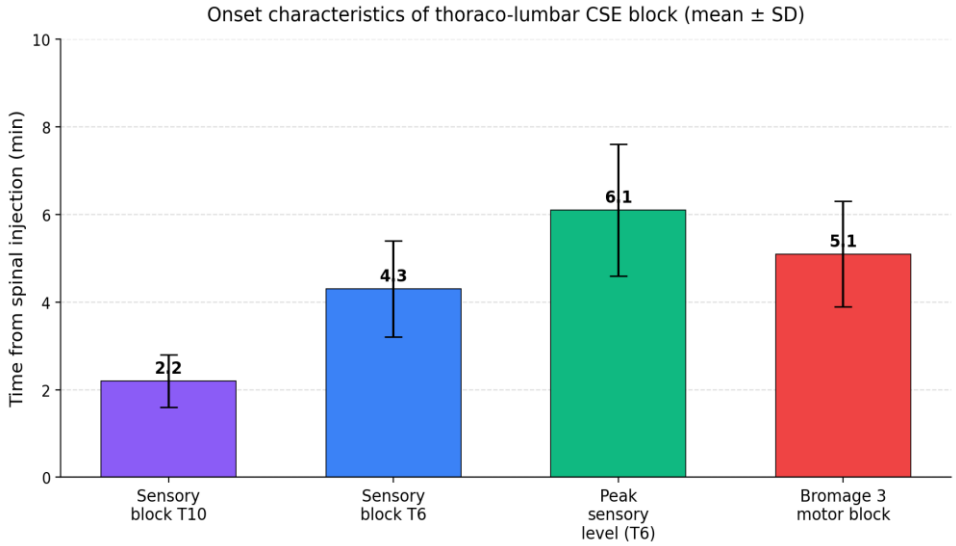

Figure 3. Onset characteristics of the thoraco-lumbar combined spinal-epidural block. Rapid onset of sensory and motor block was consistently obtained. Bars represent mean ± SD.

Haemodynamic profile

Haemodynamic changes during the intraoperative period are shown in Figure 4. A modest decrease in systolic and mean arterial pressure was observed at 5–15 minutes post-injection, returning close to baseline by 30 minutes. Twelve patients (26.7%) developed hypotension requiring ephedrine (mean total dose 18 ± 6 mg, typically three boluses of 6 mg). Bradycardia occurred in 4 (8.9%) patients, all of whom responded to a single dose of atropine.

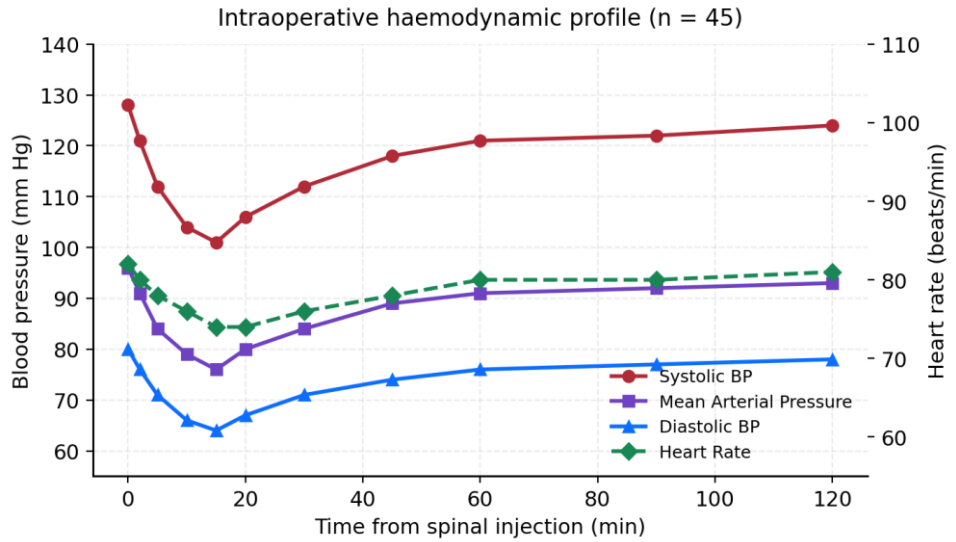

Figure 4. Intraoperative haemodynamic profile showing systolic, mean and diastolic arterial pressures (left y-axis) and heart rate (right y-axis) versus time from spinal injection. Values are means; nadir occurred between 10 and 15 minutes.

Complications and adverse events

No serious complications were observed. There were no cases of high spinal block, post-dural puncture headache, transient neurological symptoms, epidural haematoma, or catheter breakage. Minor complications are summarised in Table 3.

Table 3. Complications and adverse events (n = 45)

Event	n (%)
Hypotension (requiring vasopressor)	12 (26.7)
Bradycardia (requiring atropine)	4 (8.9)
Nausea / vomiting	5 (11.1)
Shivering	6 (13.3)
Urinary retention (>6 h)	3 (6.7)
Post-dural puncture headache	0 (0)
Transient neurological symptoms	0 (0)
Backache at 48 h	2 (4.4)
Catheter shearing / fragmentation	0 (0)
Failed technique / GA conversion	0 (0)

Postoperative analgesia

Postoperative pain scores were low and remained well controlled throughout the 48-hour observation period (Figure 5). Mean VAS at rest at 24 hours was 2.1 ± 0.8, and mean VAS on movement at the same time point was 3.1 ± 0.9. Only 4 patients (8.9%) required rescue tramadol during the first 24 hours. Ambulation was achieved in 40 patients (88.9%) by the end of postoperative day 1, and 43 (95.6%) by the end of day 2.

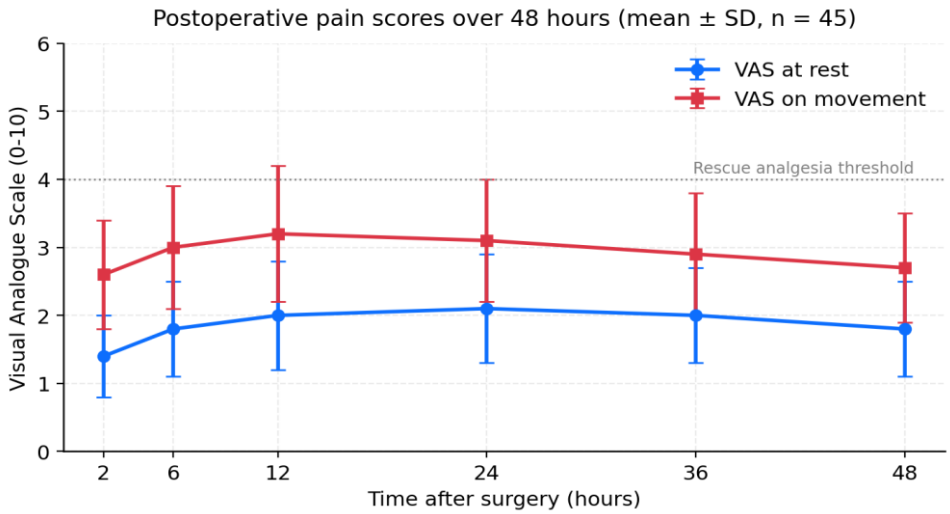

Figure 5. Postoperative visual analogue scale (VAS) pain scores at rest and on movement over the first 48 hours. The dotted line indicates the pre-defined rescue analgesia threshold (VAS 4). Values are mean ± SD.

DISCUSSION

Our prospective series of 45 women undergoing TAH under a modified thoraco-lumbar double-space CSE with the "Spinal-First, Injection-Last" workflow demonstrated 100% procedural success, uniform rapid onset of a dense surgical block up to T6, 100% catheter integrity on removal, and low pain scores throughout the first 48 postoperative hours. To the best of our knowledge, this is the first formal description of a resequenced dual-space CSE that structurally—not merely probabilistically—removes the risk of catheter shearing.

Mechanical rationale

Catheter shearing during dual-space CSE is a rare but well-documented complication. In the conventional sequence, an epidural catheter placed at L2–L3 or L3–L4 may lie within the needle path of a subsequent spinal puncture at T12–L1 or higher, and a cephalad-directed catheter tip may be transfixed by the advancing spinal needle.[19–23] Even when the puncture sites appear distant on the skin, the catheter may drift laterally in the epidural fat and cross the trajectory of the spinal needle.[39] By reversing the sequence—placing the spinal needle first, keeping it stationary, threading the catheter afterwards, and injecting the intrathecal drug only after the catheter is safely fixed—we eliminate the possibility of a moving spinal needle encountering the catheter. The

4–5 cm cephalad thread of the L1–L3 catheter reaches, at most, T12–L1, well below the stationary T11–T12 spinal needle, keeping the catheter and needle bevel physically separated.

Choice of the low-thoracic interspace

Segmental thoracic spinal anaesthesia at T9–T11 has been shown by multiple investigators to be safe and effective for upper abdominal, laparoscopic and open lower abdominal surgery.[26–28,40] Imbelloni and colleagues demonstrated, in an anatomical MRI study, that the distance between the dura and the spinal cord at T10–T12 averages 5.8–7.5 mm, sufficient to accommodate a 25G needle safely.[41] Van Zundert and colleagues reported segmental thoracic spinal anaesthesia in over 600 patients without any neurological complication.[42] The reduced dose of hyperbaric bupivacaine (7.5–12.5 mg) required at thoracic levels also lowers the risk of profound hypotension seen with equivalent lumbar doses spreading cephalad.[45] In our series, 12.5 mg of hyperbaric bupivacaine with 25 µg fentanyl consistently produced a T6 peak block with Bromage 3 motor block in a median of 5 minutes—comparable to published data for segmental thoracic spinal anaesthesia and superior to equipotent lumbar spinal doses for onset and abdominal wall relaxation.[40,43] We deliberately targeted a T6 sensory level rather than a higher T4 block, since coverage to T6 is sufficient for the T10–L1 uterine somatic afferents and T5–L2 sympathetic outflow relevant to TAH, while sparing the upper thoracic (T1–T4) cardio-accelerator fibres and diaphragmatic innervation, thereby minimising the risk of profound hypotension, bradycardia and subjective breathlessness seen with higher blocks.

Comparison with needle-through-needle CSE

The NTN CSE has become the default in many institutions because of its supposed simplicity.[12] However, several disadvantages persist: (i) the epidural catheter cannot be tested before spinal injection, so an intravascular or intrathecal catheter is only unmasked after fixed spinal anaesthesia is established;[14] (ii) the long spinal needle can drag epidural tissue or metallic microparticles into the subarachnoid space;[16] (iii) failed dural puncture despite correct epidural placement is reported in 5–16% of cases;[17] and (iv) the epidural catheter, when subsequently threaded, may migrate through the dural rent, converting the spinal into unintended continuous spinal anaesthesia.[15] Our dual-space resequenced approach avoids all four of these limitations. The epidural catheter is placed independently and can be aspirated and test-dosed with lignocaine-adrenaline before any spinal injection.[35] There is no coaxial passage of the spinal needle through the Tuohy bevel, and the risk of dural translocation of the catheter is negligible when the catheter sits at L1–L3 and the spinal puncture is at T11–T12.

Comparison with conventional dual-space CSE

The conventional dual-space sequence has the well-known through-and-through hazard already discussed. Additionally, when the epidural is placed first and dosed with a test bolus, the resulting incipient neuraxial block may make patient positioning and subsequent dural puncture at a higher interspace difficult or uncomfortable. Reversing the order, as we have done, avoids this by delaying any pharmacological effect until the technical work is complete.

Postoperative analgesia and functional recovery

The intact lumbar epidural catheter provided excellent postoperative analgesia, with a mean 24-hour VAS at rest of 2.1 and low rescue requirement. This is consistent with a substantial body of evidence supporting continuous thoracic and lumbar epidural analgesia in reducing pain scores, opioid consumption, pulmonary complications and length of stay after major abdominal surgery.[38,44,45] Early ambulation, achieved in the majority of our patients by the end of postoperative day 1, is an important element of enhanced recovery after surgery (ERAS) pathways for gynaecological surgery.[46]

Safety profile

The complication profile in our series compares favourably with published CSE data. The 26.7% incidence of hypotension is comparable to the 20–40% reported for lumbar CSE with similar doses.[47] There were no cases of post-dural puncture headache; the use of a 25G Quincke needle and a single dural puncture likely contributed to this. Importantly, there were no cases of catheter shearing, transient neurological symptoms, or persistent neurological deficit.

Limitations

Our study has several limitations. First, it is an observational series without a randomised comparator arm; head-to-head trials against NTN CSE and conventional dual-space CSE are needed to confirm superiority. Second, the sample size of 45 is modest and precludes precise estimation of the incidence of very rare complications such as catheter shearing or permanent neurological injury. Third, the technique requires proficiency in thoracic neuraxial access and may not be immediately transferable to trainees or low-volume settings without appropriate training. Fourth, the paramedian approach at T11–T12, while anatomically favourable, requires familiarity that may not be universal.[48,49]

Future directions

Randomised controlled trials comparing the "Spinal-First, Injection-Last" thoraco-lumbar CSE with standard techniques for TAH and other lower abdominal surgeries are warranted. Pre-procedural ultrasound guidance may further increase the safety and reproducibility of the thoracic puncture, particularly in patients with challenging anatomy.[50].

CONCLUSION

The "Spinal-First, Injection-Last" thoraco-lumbar double-space CSE technique is a simple, anatomically precise resequencing of the standard dual-space approach that structurally eliminates the risk of epidural catheter shearing by the spinal needle. In our series of 45 women undergoing TAH, the technique delivered rapid, dense, T6-level surgical anaesthesia with 100% catheter integrity, stable intraoperative haemodynamics, and excellent postoperative analgesia via the intact lumbar epidural catheter. This modification preserves all the clinical advantages of CSE—rapid onset, dense block, prolonged analgesia—while removing one of its most feared, if uncommon, mechanical complications. It merits wider evaluation in prospective randomised trials.

REFERENCES

1. Wright JD, Herzog TJ, Tsui J, Ananth CV, Lewin SN, Lu YS, et al. Nationwide trends in the performance of inpatient hysterectomy in the United States. Obstet Gynecol. 2013;122(2 Pt 1):233–41.
2. Committee on Gynecologic Practice. ACOG Committee Opinion No. 701: Choosing the route of hysterectomy for benign disease. Obstet Gynecol. 2017;129(6):e155–9.
3. Guay J, Choi P, Suresh S, Albert N, Kopp S, Pace NL. Neuraxial blockade for the prevention of postoperative mortality and major morbidity: an overview of Cochrane systematic reviews. Cochrane Database Syst Rev. 2014;(1):CD010108.
4. Rodgers A, Walker N, Schug S, McKee A, Kehlet H, van Zundert A, et al. Reduction of postoperative mortality and morbidity with epidural or spinal anaesthesia: results from overview of randomised trials. BMJ. 2000;321(7275):1493.
5. Pöpping DM, Elia N, Van Aken HK, Marret E, Schug SA, Kranke P, et al. Impact of epidural analgesia on mortality and morbidity after surgery: systematic review and meta-analysis of randomized controlled trials. Ann Surg. 2014;259(6):1056–67.
6. Greene NM. Distribution of local anesthetic solutions within the subarachnoid space. Anesth Analg. 1985;64(7):715–30.
7. Bromage PR. Epidural analgesia. Philadelphia: WB Saunders; 1978.
8. Hermanides J, Hollmann MW, Stevens MF, Lirk P. Failed epidural: causes and management. Br J Anaesth. 2012;109(2):144–54.
9. Cook TM. Combined spinal-epidural techniques. Anaesthesia. 2000;55(1):42–64.
10. Rawal N, Van Zundert A, Holmström B, Crowhurst JA. Combined spinal-epidural technique. Reg Anesth. 1997;22(5):406–23.
11. Simmons SW, Taghizadeh N, Dennis AT, Hughes D, Cyna AM. Combined spinal-epidural versus epidural analgesia in labour. Cochrane Database Syst Rev. 2012;(10):CD003401.
12. Rawal N. Combined spinal-epidural anaesthesia. Curr Opin Anaesthesiol. 2005;18(5):518–21.
13. Lyons G, Macdonald R, Mikl B. Combined epidural/spinal anaesthesia for caesarean section. Through the needle or in separate spaces? Anaesthesia. 1992;47(3):199–201.
14. Herbstman CH, Jaffee JB, Tuman KJ, Newman LM. An in vivo evaluation of four spinal needles used for the combined spinal-epidural technique. Anesth Analg. 1998;86(3):520–2.
15. Holmström B, Rawal N, Axelsson K, Nydahl PA. Risk of catheter migration during combined spinal epidural block: percutaneous epiduroscopy study. Anesth Analg. 1995;80(4):747–53.
16. Eldor J, Guedj P, Cotev S. Epidural metal detection following combined spinal-epidural anesthesia. J Clin Anesth. 1994;6(4):349–51.
17. Blanshard HJ, Cook TM. Use of combined spinal-epidural by obstetric anaesthetists. Anaesthesia. 2004;59(9):922–3.
18. Casati A, D'Ambrosio A, De Negri P, Fanelli G, Tagariello V, Tarantino F. A clinical comparison between needle-through-needle and double-segment techniques for combined spinal and epidural anesthesia. Reg Anesth Pain Med. 1998;23(4):390–4.
19. Ferguson S, Brighouse D. Damage to epidural catheters caused by spinal needles inserted through the epidural catheter. Anaesthesia. 2001;56(5):485.
20. Blackshear RH. Rupture of epidural catheters during combined spinal-epidural anesthesia. Anesth Analg. 1994;79(1):189.
21. Levy DM. Traumatic damage to epidural catheters. Int J Obstet Anesth. 1994;3(3):172.
22. Mitra R, Fleischmann K. Management of the sheared epidural catheter: is surgical extraction really necessary? J Clin Anesth. 2007;19(4):310–4.
23. Ateş Y, Yuenç CA, Ünlü MA, Saygın B, Akkaya S. The mechanical properties of intact and traumatized epidural catheters. Anesth Analg. 2000;90(2):393–9.
24. Bonica JJ. The nature of pain of parturition. Clin Obstet Gynaecol. 1975;2(3):499–516.
25. Brown DL. Spinal, epidural, and caudal anesthesia. In: Miller RD, editor. Miller's Anesthesia. 7th ed. Philadelphia: Churchill Livingstone; 2010. p. 1611–38.
26. Imbelloni LE, Fornasari M, Fialho JC, Sant'Anna R, Cordeiro JA. General anesthesia versus spinal anesthesia for laparoscopic cholecystectomy. Rev Bras Anestesiol. 2010;60(3):217–27.
27. Ellakany M. Thoracic spinal anesthesia is safe for patients undergoing abdominal cancer surgery. Anesth Essays Res. 2014;8(2):223–8.
28. Van Zundert AA, Stultiens G, Jakimowicz JJ, Peek D, van der Ham WG, Korsten HH, et al. Laparoscopic cholecystectomy under segmental thoracic spinal anaesthesia: a feasibility study. Br J Anaesth. 2007;98(5):682–6.

29. World Medical Association. World Medical Association Declaration of Helsinki: ethical principles for medical research involving human subjects. JAMA. 2013;310(20):2191–4.
30. Bujang MA, Adnan TH. Requirements for minimum sample size for sensitivity and specificity analysis. J Clin Diagn Res. 2016;10(10):YE01–6.
31. American Society of Anesthesiologists Task Force on Preoperative Fasting. Practice guidelines for preoperative fasting and the use of pharmacologic agents to reduce the risk of pulmonary aspiration. Anesthesiology. 2017;126(3):376–93.
32. Mercier FJ, Diemunsch P, Ducloy-Bouthors AS, Mignon A, Fischler M, Malinovsky JM, et al. 6% Hydroxyethyl starch (130/0.4) vs Ringer's lactate preloading before spinal anaesthesia for caesarean delivery. Br J Anaesth. 2014;113(3):459–67.
33. Chakraverty R, Pynsent P, Isaacs K. Which spinal levels are identified by palpation of the iliac crests and the posterior superior iliac spines? J Anat. 2007;210(2):232–6.
34. Beilin Y, Bernstein HH, Zucker-Pinchoff B. The optimal distance that a multiorifice epidural catheter should be threaded into the epidural space. Anesth Analg. 1995;81(2):301–4.
35. Guay J. The epidural test dose: a review. Anesth Analg. 2006;102(3):921–9.
36. Ben-David B, Solomon E, Levin H, Admoni H, Goldik Z. Intrathecal fentanyl with small-dose dilute bupivacaine: better anesthesia without prolonging recovery. Anesth Analg. 1997;85(3):560–5.
37. Bromage PR. A comparison of the hydrochloride and carbon dioxide salts of lidocaine and prilocaine in epidural analgesia. Acta Anaesthesiol Scand Suppl. 1965;16:55–69.
38. Wu CL, Cohen SR, Richman JM, Rowlingson AJ, Courpas GE, Cheung K, et al. Efficacy of postoperative patient-controlled and continuous infusion epidural analgesia versus intravenous patient-controlled analgesia with opioids: a meta-analysis. Anesthesiology. 2005;103(5):1079–88.
39. Muranaka K, Mizutani H, Seo K, Yoshida M. A comparison between epidural anesthesia with paramedian approach versus median approach. Masui. 2001;50(10):1085–8.
40. Kejriwal R, Kumar R. Segmental thoracic spinal anaesthesia for laparoscopic cholecystectomy. J Anaesthesiol Clin Pharmacol. 2015;31(2):265–6.
41. Imbelloni LE, Quirici MB, Ferraz-Filho JR, Cordeiro JA, Ganem EM. The anatomy of the thoracic spinal canal investigated with magnetic resonance imaging. Anesth Analg. 2010;110(5):1494–5.
42. Van Zundert AA, Stultiens G, Jakimowicz JJ, van den Borne BE, van der Ham WG, Wildsmith JA. Segmental spinal anaesthesia for cholecystectomy in a patient with severe lung disease. Br J Anaesth. 2006;96(4):464–6.
43. Imbelloni LE, Pitombo PF, Ganem EM. The incidence of paresthesia and neurologic complications after lower spinal thoracic puncture with cut needle compared to pencil-point needle. J Anesth Clin Res. 2010;1:106.
44. Block BM, Liu SS, Rowlingson AJ, Cowan AR, Cowan JA Jr, Wu CL. Efficacy of postoperative epidural analgesia: a meta-analysis. JAMA. 2003;290(18):2455–63.
45. Guay J, Nishimori M, Kopp S. Epidural local anaesthetics versus opioid-based analgesic regimens for postoperative gastrointestinal paralysis, vomiting and pain after abdominal surgery. Cochrane Database Syst Rev. 2016;7:CD001893.
46. Nelson G, Bakkum-Gamez J, Kalogera E, Glaser G, Altman A, Meyer LA, et al. Guidelines for perioperative care in gynecologic/oncology: Enhanced Recovery After Surgery (ERAS) Society recommendations—2019 update. Int J Gynecol Cancer. 2019;29(4):651–68.
47. Klimscha W, Weinstabl C, Ilias W, Mayer N, Kashanipour A, Schneider B, et al. Continuous spinal anesthesia with a microcatheter and low-dose bupivacaine decreases the hemodynamic effects of centroneuraxis blocks in elderly patients. Anesth Analg. 1993;77(2):275–80.
48. Broadbent CR, Maxwell WB, Ferrie R, Wilson DJ, Gawne-Cain M, Russell R. Ability of anaesthetists to identify a marked lumbar interspace. Anaesthesia. 2000;55(11):1122–6.
49. Furness G, Reilly MP, Kuchi S. An evaluation of ultrasound imaging for identification of the lumbar intervertebral level. Anaesthesia. 2002;57(3):277–80.
50. Chin KJ, Karmakar MK, Peng P. Ultrasonography of the adult thoracic and lumbar spine for central neuraxial blockade. Anesthesiology. 2011;114(6):1459–85.